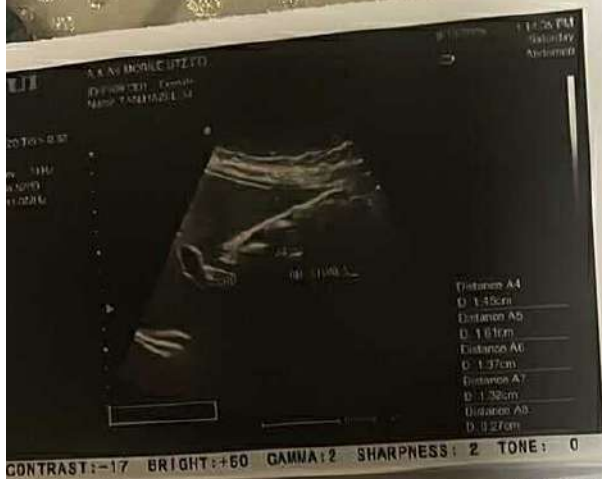



ATORY INC.

Zone 12, Baybay City, Leyte

skmrslabinc@gmail.com

Date: 09/13/2025

Age/Gender: 34 years old/Female

Physician: Dr. Latido

SONOGRAPHIC REPORT

MEASUREMENTS:

Liver span: 13.2 cm (along the renal axis)
 Gallbladder: 1.8 cm ; wall: 0.2 cm
 Common bile duct: 0.2 cm
 Pancreas: 1.6, 0.8, 1.7 cm (head, body, tail)
 Spleen: 8.7 x 4.2 cm (LH)
 Right kidney: 9.6 x 4.8 x 3.7 cm (LWH) ; Cortical thickness: 1.0 cm
 Left kidney: 10.4 x 4.8 x 4.6 cm (LWH) ; Cortical thickness: 1.6 cm
 Urinary bladder: 0.2 cm in wall thickness
 Uterus: 6.3 x 5.1 x 3.6 cm (LWH) ; Endometrial echo: 0.5 cm
 Abdominal aorta: 1.2 cm

FINDINGS:

The liver is normal in size. There is homogenous and uniform echopattern. The hepatic border is smooth. No abnormal solid or cystic mass lesion noted. The intrahepatic ducts are not dilated.

The gallbladder is normal in size intraluminally. The wall is smooth and not thickened. There are multiple, concave-shaped and highly echogenic structures measuring up to 1.8 cm in diameter, seen in the gallbladder neck, with significant posterior acoustic shadowing. The common duct is not dilated.

The visualized pancreas and spleen are normal in size with homogeneous echo pattern. No abnormal solid or cystic mass lesion noted.

Both kidneys are normal in size and configuration. No lithiasis or hydronephrosis noted. Both renal cortices are hypoechoic relative to the liver and spleen. The corticomedullary junctions are well delineated. There is no solid or cystic mass lesion noted. Both proximal ureters are not dilated.

No ascites noted.

The urinary bladder is well distended. The wall is smooth and not thickened. There is no lithiasis or intraluminal mass noted.

The uterus is normal in size and anteverted in position. The endometrial echo is hyperechoic and intact. There is no abnormal myometrial solid or cystic mass lesion noted. Both adnexae are unremarkable. There is no fluid in the posterior cul de sac.

The abdominal aorta is normal in course and caliber. No enlarged para aortic lymph node noted.

IMPRESSION:

- CHOLECYSTOLITHIASES, AS DESCRIBED, WITHOUT EVIDENCE OF ACUTE CHOLECYSTITIS.
- NORMAL SONOGRAPHIC EVALUATION OF THE LIVER, KIDNEYS, PANCREAS, SPLEEN AND ABDOMINAL AORTA.
- INTRAHEPATIC AND COMMON BILE DUCTS ARE NOT DILATED.
- WELL DISTENDED URINARY BLADDER.
- NORMAL SIZE AND ANTEVERTED UTERUS.
- INTACT AND HYPERECHOIC ENDOMETRIAL ECHO.
- UNREMARKABLE STUDY OF BOTH ADNEXAE.
- NO FLUID COLLECTION IN THE POSTERIOR CUL DE SAC.

MA. FLOR ANNE ESPINA QUIANZON, M.D., PSUCM

The findings of this report are only based on sonographic interpretation. Correlation with clinical and laboratory findings are recommended. Thank you for referring.

JOHN CHRISTOPHER A. DE VERA

GENERAL SURGERY

Ground Floor, Pongos Hotel
Bonifacio St., Ormoc City
OFFICE:
☎ (053) 255-7906 / 560-8064

CLINIC HOURS:
Monday - Saturday:
By Appointment

Name of Patient: Rn, Mary Age: 30 Sex: F


Address: B4 C4, L4 Date: 8/11/15

Rx

This is to certify that I have
examined Mrs. Rn. and a degree
of childbearing. She is able to
get pregnant.

Thank you

Next checkup:


JOHN CHRISTOPHER A. DE VERA
License. No. 0120861
PTR No.



LEYTE BAPTIST HOSPITAL, INC.

6524 Hilongos, Leyte, Philippines

Tel. # 336-2105 / Telefax: 567-9457

" Preach the word and heal the sick " Luke 9:6

MEDICAL CERTIFICATE

September 15, 2025

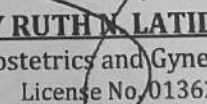
TO WHOM IT MAY CONCERN:

This is to certify that, **HAZEL ALENA DIAMANTE TAN, 34 years old, female** and residing in **VSU, BAYBAY CITY, LEYTE**, was seen at OPD on **September 02, 2025**, and had a follow-up checkup on **September 10, 2025**, for the following:

Diagnosis: NULLIGRAVID R/I HORMONAL IMBALANCE

**Remarks: PATIENT SEEN AND EXAMINED AS OUT PATIENT ONLY
HOME MEDICATIONS WERE PRESCRIBED**

This certification is issued upon the request of **Hazel Alena D. Tan** for employment purposes.


IVY RUTH N. LATIDO, MD
Obstetrics and Gynecology
License No. 0136224



LEYTE BAPTIST HOSPITAL, INC.

6524 Hilongos, Leyte, Philippines

Tel. # 336-2105 / Telefax: 567-9457

" Preach the word and heal the sick " Luke 9:6

MEDICAL CERTIFICATE

September 17, 2025

Date

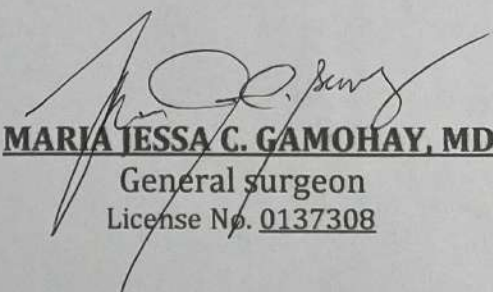
TO WHOM IT MAY CONCERN:

This is to certify that, **HAZEL ALENA D. TAN, 34 years old** and residing in **VSU, BAYBAY CITY, LEYTE** was seen at OPD on September 17, 2025 for the following:

Diagnoses: CHOLECYSTOLITHISIS

Remarks: Advise for surgery

This certification is issued upon the request of patient for employment purposes.


MARIA JESSA C. GAMOHAY, MD.

General surgeon

License No. 0137308



LEYTE BAPTIST HOSPITAL, INC.

6524 Hilongos, Leyte, Philippines

Tel. # 336-2105 / Telefax: 567-9457

" Preach the word and heal the sick " Luke 9:6

MEDICAL CERTIFICATE

September 17, 2025

TO WHOM IT MAY CONCERN:

This is to certify that, **HAZEL ALENA DIAMANTE TAN, 34 years old, female** and residing in **VSU, BAYBAY CITY, LEYTE**, was seen at OPD on **September 17, 2025**, for the following:

Diagnosis: NULLIGRAVID
CHOLECYSTOLITHIASIS
T/C ENDOMETRIOSIS

Remarks: TREATED AS OUT PATIENT AND PRESCRIBED WITH HOME MEDICATIONS
REFERRED TO A GENERAL SURGEON FOR EVALUATION AND MANAGEMENT

This certification is issued upon the request of **Hazel Alena D. Tan** for employment purposes.

IVY RUTH N. LATIDO, MD
Obstetrics and Gynecology
License No. 0136224