



11 April 2024

DR. PROSE IVY G. YEPES

University President, Visayas State University
ViSCA, Baybay City, Leyte

Dear **Dr. Yepes**:

Greetings!

Please allow me to monetize at least 50% of my leave credits. I need additional financial resources to provide for my father's medication. The attached medical test results are from my father's Blood Chemistry, Urinalysis, and Ultrasound conducted on Nov. 6 & 7, 2023 after he experienced excruciating pain in his abdomen. Dr. Mante, my father's attending physician, strongly recommended that he be admitted to a hospital because of kidney disease and liver cirrhosis. My father refused to be admitted to the hospital, but he has been taking herbal medications such as King's Herbal and Intra. It seems that these herbal medications are quite effective since my father is no longer suffering from the same pain he had felt before, although I feel the need to have him undergo a follow-up check-up. King's Herbal and Intra are too costly, each costing almost P2,000, and my father consumes one bottle of each per week, which means we have to spend P4,000 per week. This is on top of my father's other maintenance medications for high blood, diabetes, and rheumatism. For these reasons, please allow me to monetize my leave credits so it can help me provide for my father's medications.

I hope this humble request merits your kind consideration. Thank you so much, maam, and God bless you and your family.

Respectfully yours,


Engr. Marcelo T. Abrera, Jr.
Faculty Member, Department of Civil Engineering

Recommending Approval:

Dr. Edgardo E. Tulin
Vice-President for Administration and Finance

Approved:

Dr. Prose Ivy G. Yepes
University President
Visayas State University



Kempis St, Dulag, Leyte

XRAY * ULTRASOUND

Patient's Name: ABRERA, MARCELO Age: 69 Sex: M Status:
Address: DULAG, LEYTE Requesting Physician: DR. MANTE
U/S No. 8690 Date: 11-06-2023 Name of Examination: WHOLE ABDOMEN

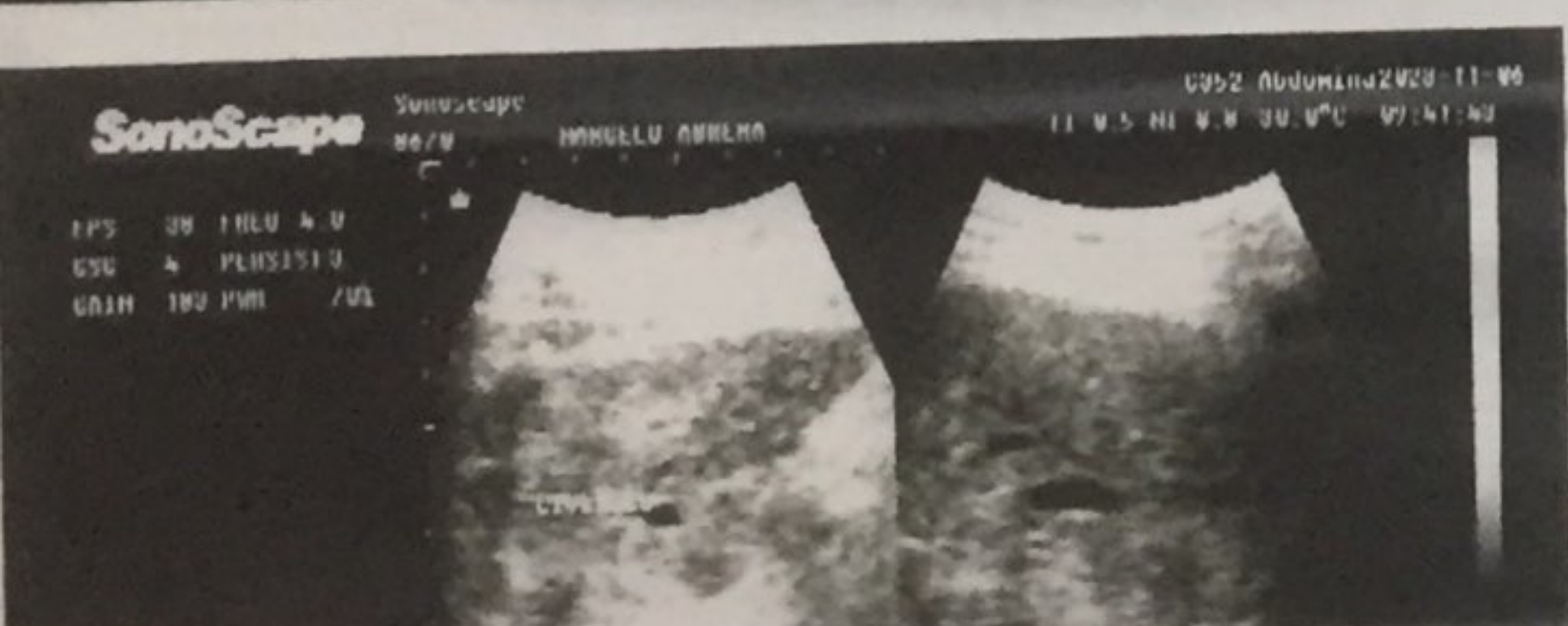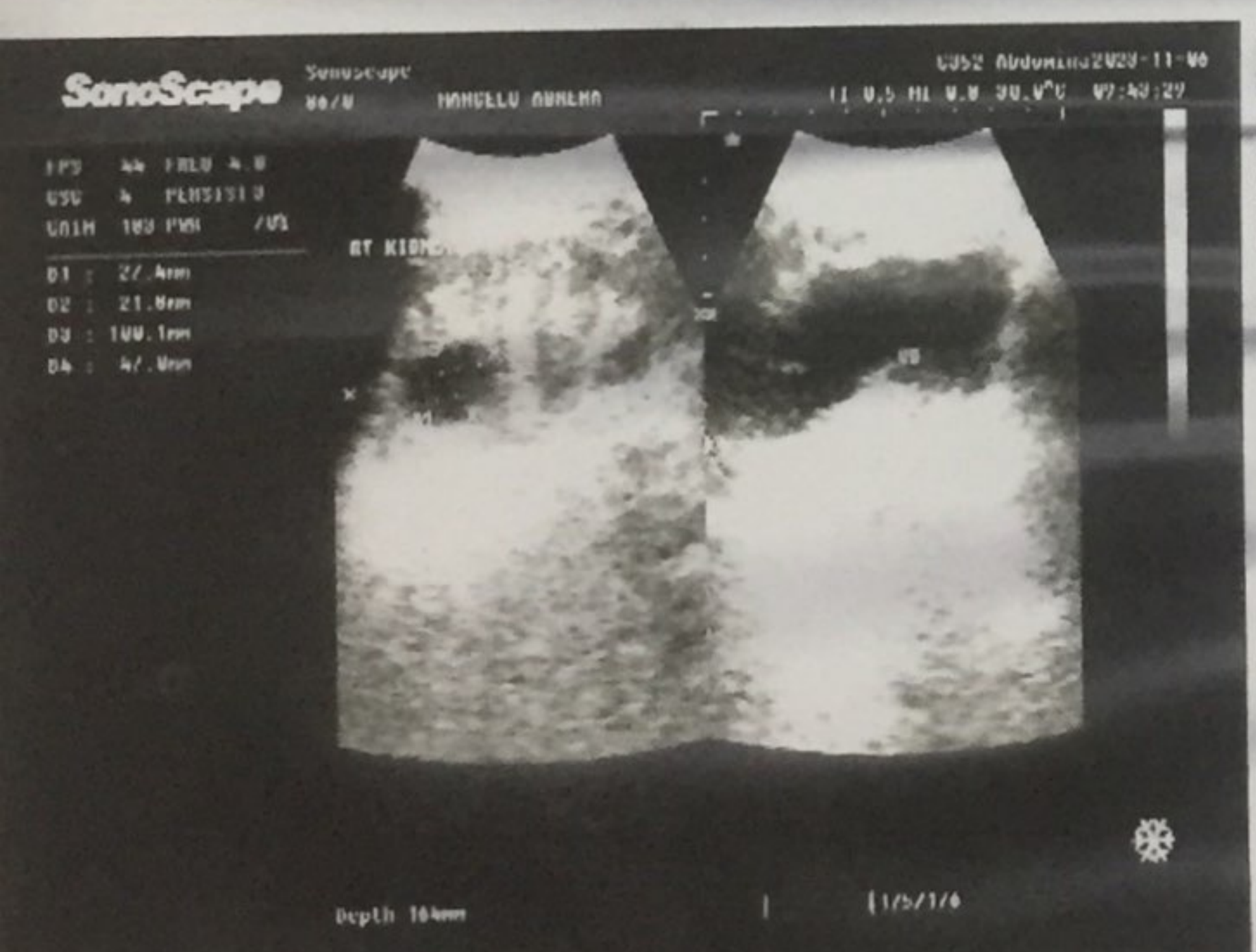
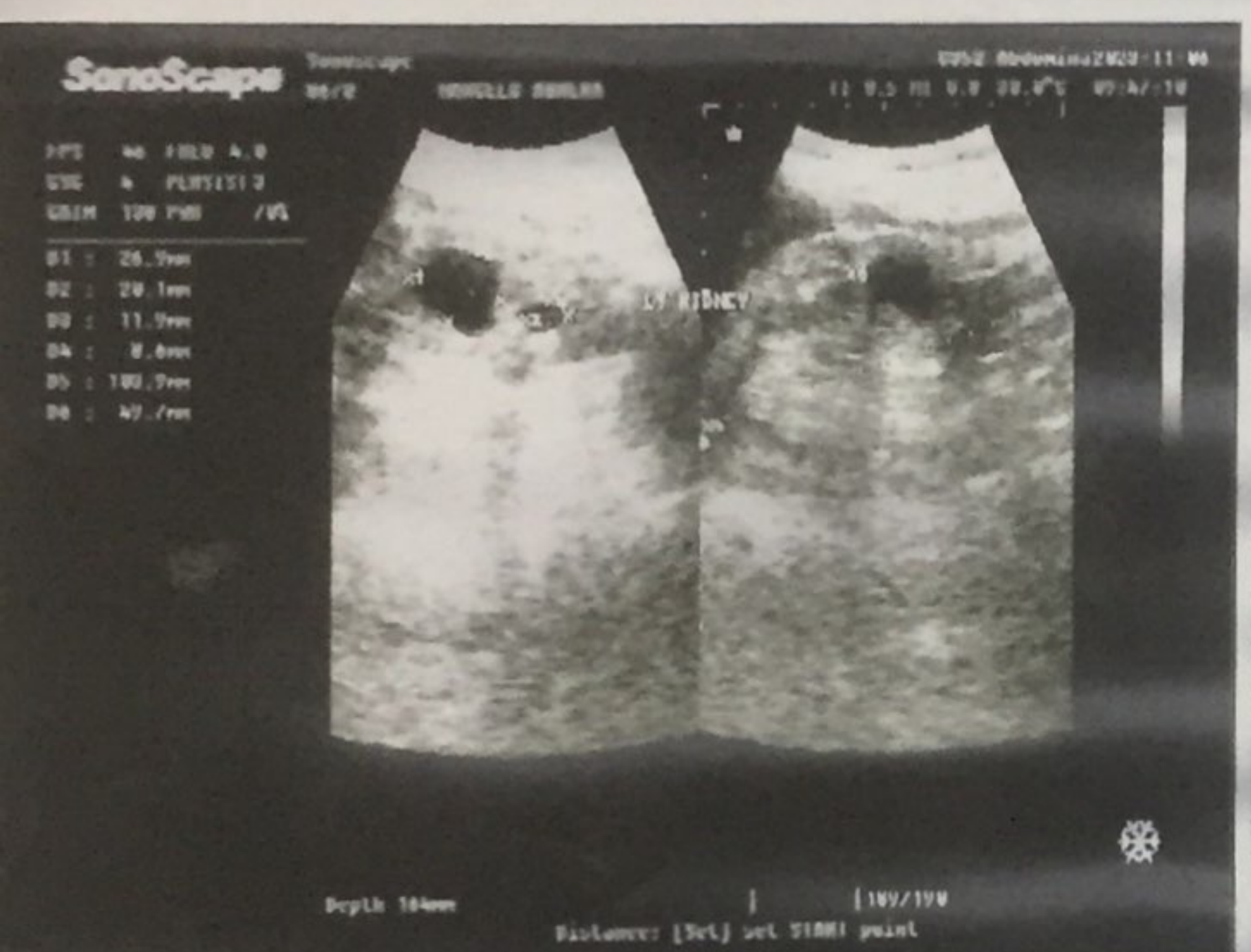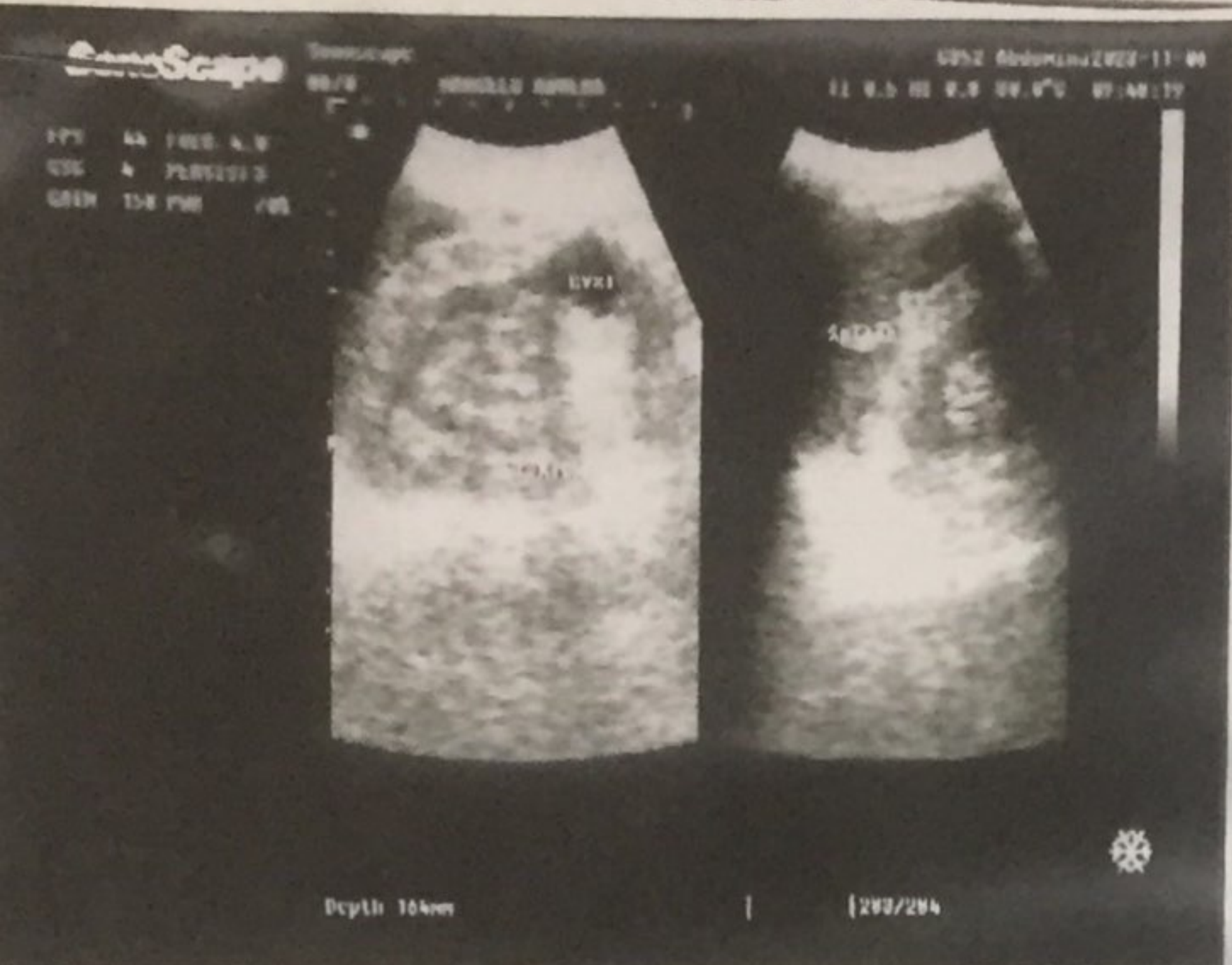
ULTRASOUND REPORT

The liver has a normal size and coarse parenchymal echotexture with lacelike echogenecities. No hepatic mass. Intact intrahepatic ducts, CBD and vascular channels.
The gallbladder measures 2.6 x 1.3 cm. Wall is smooth and thin. No intraluminal echoes.
The pancreas and the spleen have normal sizes and echotexture.
The kidneys measure: right = 10.0 x 4.7 cm; left = 10.3 x 4.9 cm. Both kidneys have coarse parenchymal echotexture, sandy stones and cortical cysts measuring 2.7 x 2.1 cm in the right and 2.6 x 2.0 cm and 1.1 x 0.8 cm in the left. No ectasia.
The ureters are not dilated.
The urinary bladder has a smooth and thin wall. No intraluminal echoes.
No intra-abdominal mass nor free fluid collection.

IMPRESSION: * Liver cirrhosis secondary to schistosomiasis.
* Partially contracted gallbladder.
* Renal parenchymal disease, grade 1, sandy nephrolithiasis and renal cortical cysts, bilateral.
* Normal pancreas, spleen and urinary bladder.
* Non-dilated biliary tree and ureters.


JOSEPHINE Y. SEQUITO, M.D., D.P.B.R.
Radiologist
Diplomate: Philippine College of Radiology

This report is based on sonographic findings.
Clinical correlation is suggested.
Thank you for your referral



R.G. CLINICAL LABORATORY

Narra cor. Barayong sts. San Jose , Dulag Leyte 6505

Mobile no. 0932 271 7985

NAME : **ABRERA , MARCELO**AGE/SEX : **69 / M**DATE: **11 / 07 / 2023**PHYSICIAN: DR. MANTE**URINALYSIS**

		MICROSCOPIC:	
COLOR	Yellow	PUS CELLS	2 - 5 / HPF
TRANSPARENCY	Cloudy	RBC	0 - 2 / HPF
PH	6.0	Epithelial cells	None
SPECIFIC GRAVITY	1.020	a. urates	FEW
SUGAR	++	BACTERIA	Moderate
PROTEIN	++++	Yeast cells	Few

REMARKS:**CLEOCITA P. PORTULA M.D**

PATHOLOGIST

0094389

MR. ANELOU C. GARVEZ, RMT

MEDICAL TECHNOLOGIST

LIC. NO. 0038462

R.G. CLINICAL LABORATORY

Narra cor. Barayong Sts., San Jose, Dulag, Leyte 6505

MOBILE NO. 0932 271 7985

NAME: ABRERA, MARCELO
PHYSICIAN: DR. MANTEAGE/SEX: 69 / MDATE: 11 / 07 / 2023BLOOD CHEMISTRY

LABORATORY TEST	RESULT	REFERENCE VALUE
FBS	<u>11.3</u>	4.2 --- 6.4 mmol/L
TOTAL CHOLESTEROL	3.73	Less than 5.15 mmol/L
HDL - CHOLESTEROL	0.79	Male: up to 1.42; Female: up to 1.68 mmol/L
LDL - CHOLESTEROL	2.31	Up to 4.11 mmol/L
TRIGLYCERIDES	1.09	0.40 --- 1.83 mmol/L
CREATININE	<u>402.1</u>	Male: 81.8 - 136.3 ; Female: 63.6 --- 118.1 umol/L
BUN		2.5 -- 6.5 mmol/L
URIC ACID	<u>498</u>	Male: 203 --- 417 ; Female: 143 --- 340 umol/L
AST (SGOT)	25	Male: less than 42; Female: less than 32 U/L
ALT (SGPT)	10	Male: less than 38 ; Female: less than 32 U/L
SODIUM	<u>121.6</u>	135.0 -- 145.0 mmol/L
POTASSIUM	3.31	3.50 --- 5.50 mmol/L
CALCIUM (ionized)	0.95	1.10 -- 1.35 mmol/L
CHLORIDE	83.7	96.0 - 110.0 mmol/L

REMARKS: **CREATININE & GLUCOSE** has been rechecked by the other Analyzer
SODIUM has been rechecked twice.
CLEOCITA P. PORTULA M.D
PATHOLOGIST
0094389
MR. ANELOU C. GARVEZ, RMT.
MEDICAL TECHNOLOGIST
LIC. NO. 0038462