



## LOAYON OB-GYN ULTRASOUND AND CLINIC

Room 111 Ormoc Doctors' Clinic

Cellphone # 0963-3739942

### FIRST TRIMESTER ULTRASOUND

Name:	PHLOEM GALUPO	Date: AUGUST 16,, 2025
Referring Physician:	Dr. Lourdes Divera	Age: 37 yrs. old
LMP:	January 16, 2025 (DAY)	OB Score: G1P0
Chief complaint:	G1P0 Pregnancy uterine 7 weeks 4 days AOG by LMP S/P Right ovarian cystectomy for Dermoid Cyst	

**CROWN LUMP LENGTH:** 5.8mm approximately 6 weeks age of gestation.

**CERVIX:** 3.0cmx1.8cmx2.2cm, (L x H x W), long closed, homogenous stroma and no lesion

**UTERUS:** 5.5cmx5.1cmx6.3cm, (L x H x W), vol 90.9cc, anteverted with no myometrial lesions.

**RIGHT OVARY:** 3.3cmx1.8cmx2.1cm, (L x H x W), vol. 6.5cc, normal in size and echotexture.

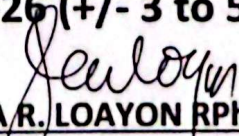
**LEFT OVARY:** 4.2cmx2.0cmx2.4cm, (L x H x W), vol. 10.8cc, normal in size and echotexture with corpus luteum.

**CUL- DE-SAC:** (+) free fluid

**OTHERS:** Subchorionic hemorrhage at the superior pole measuring 1.2x 0.9x1.6 cm vol. 0.9 cc.

### IMPRESSION:

**SINGLE LIVE INTRAUTERINE PREGNANCY**  
**6 WEEKS AOG BY CROWN RUMP LENGTH (3.2 mm)**  
**EMBRYO WITH CARDIAC ACTIVITY (FHT= 116 BPM)**  
**YOLK SAC (3.3mm)**  
**SUBCHORIONIC HEMORRHAGE AS DESCRIBED**  
**NORMAL OVARIES WITH CORPUS LUTEUM, LEFT**  
**EDD BY ULTRASOUND: March 11, 2026 (+/- 3 to 5 days)**

  
**MARJORIE MYRNA R. LOAYON RPh, MD, FPOGS, FPSUOG**  
**OB Gyn Ultrasound Sub Specialist**

**Thank you for the referral!**

*The impression is based on ultrasound imaging measurements and observations. To be clinically useful, please correlate with the patient's history, physical examination and other ancillary tests.*